

# Case study: restoring form and function with implants and veneers

**Nilesh Parmar** tackles a patient's neglected dentition to restore their smile without resorting to the 'Hollywood' look

This patient presented with a view to improving his entire smile. He was aware that he had neglected his teeth over the years, and wanted treatment on his entire mouth (Figure 1).

Medically, he was fit and well. He had been a smoker, but had given up three years previously.

Extraoral findings were normal, with adequate oral hygiene in all quadrants. The patient's BPE scores were 112 and 211. The patient admitted to not always brushing before he went to bed. He did not floss and occasionally used mouthwash.

Intraorally he had a large edentulous area in the lower right and upper left areas of his mouth. This made eating difficult as he had very few posterior contacts to masticate with. He had a crown with poor margins on the UL2, and various amalgam fillings that required replacing. The UR2 was heavily compromised, with little actual tooth tissue remaining.

The patient's specific demands were to have a nicer, whiter smile, with some back teeth to eat with.

Various treatment options were discussed, and a combined restorative/perio/implant/

**Dr Nilesh R Parmar BDS (Lond) MSc (ProsthDent) MSc (ImpDent) Cert.Ortho** runs a successful five-surgery practice close to London and is a visiting implant dentist to a central London practice.

He is one of the few dentists in the UK to have a degree from all three London dental schools and has recently obtained his certificate in Orthodontics from Warwick University. His main area of interest is in dental implants and Cerec CAD/CAM technology.

He offers training and mentoring to dentists starting out in implant dentistry, more information can be found on his website [www.drnileshparmar.com](http://www.drnileshparmar.com).

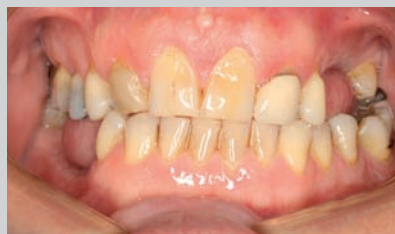

Figure 1: The patient at presentation

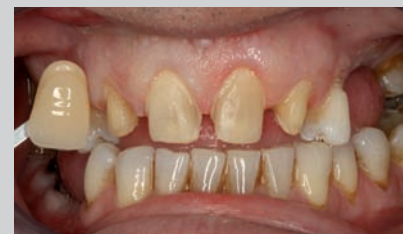

Figure 2: Shade capture

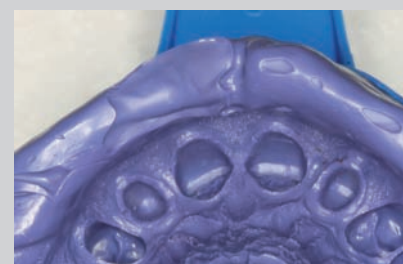

Figure 3: Impregum impression capturing preparations for veneers and crowns

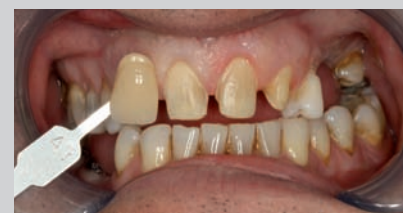

Figure 4: Stump shade capture

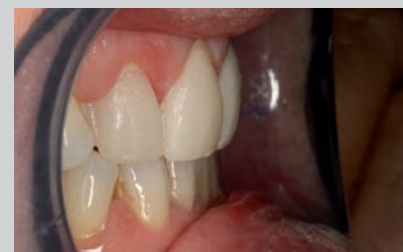
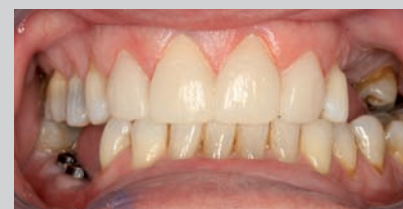
Figure 5a and 5b: Provisionals made using Luxatemp B1

cosmetic treatment plan was devised:

- Oral hygiene advice
- Hygienist visit to reinforce the above
- Full volume CBCT scan of both jaws
- Upper and lower study models and diagnostic wax ups
- Upper and lower tooth whitening using Enlighten
- Implant placement in the lower right edentulous area
- Veneer preps on the upper central incisors
- Crown preps on both lateral incisors
- Replacement of all amalgam restorations with composite/Cerec restorations
- Fitting of a three-unit screw-retained implant bridge in the lower right edentulous area
- Fitting of E.max veneers and crowns on the upper incisors
- Review appointment
- Regular six-monthly examinations and hygienist visits

The patient was keen not to have too much of a 'Hollywood smile' and wanted a more natural masculine smile. Numerous wax ups were made and edited until we were happy with the final prototypes.

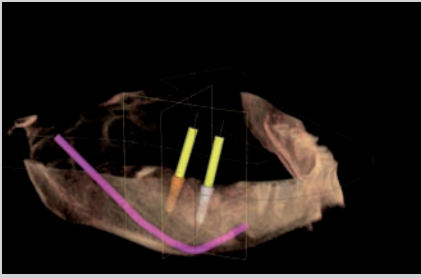
As with all smile makeover cases, the prototypes proved invaluable in reaffirming the proposed wax ups. The teeth were prepared and Luxatemp B1 prototypes were fabricated using the putty mask provided by the lab. The patient requested some minor contour changes, and this information was used when the final E.max restorations were made.

The final restorations were made at the same time as the implant bridge in order to successfully manage the patient's occlusion. The E.max restorations were bonded on with Variolink II.

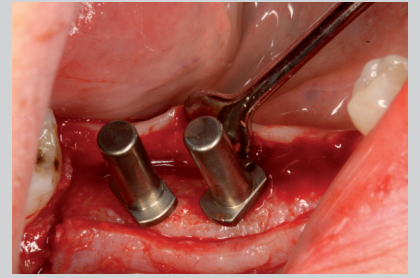
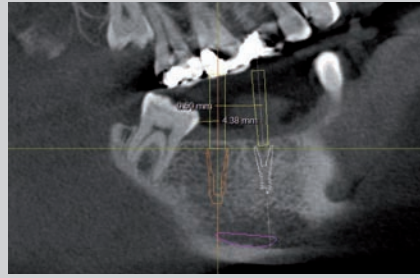
Figures 2 to 5 show the veneer process.

## Implant treatment

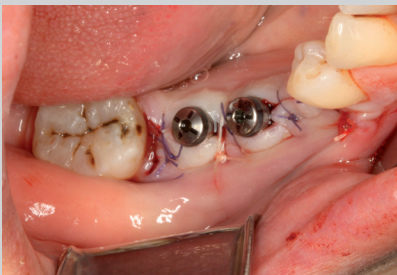During the consultation process, the patient was not keen on having any form of internal or external sinus lift in order to place implants in the upper left edentulous



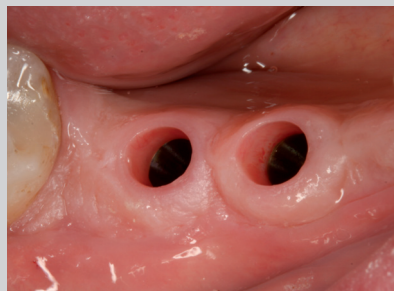
**Figure 6a and 6b:** Galileos CBCT Scan showing ID nerve and implant planning



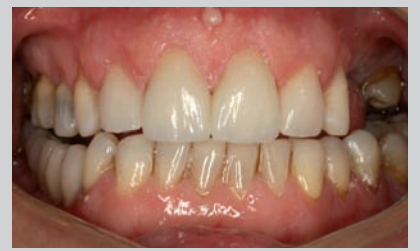**Figure 7:** Surgical picture showing parallel implant placement with guide pins



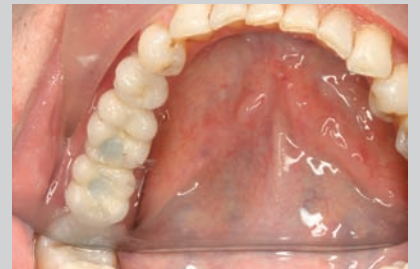**Figure 8:** Closure of surgical site with 5,0 PGA sutures and 4mm Astra Tech healing abutments



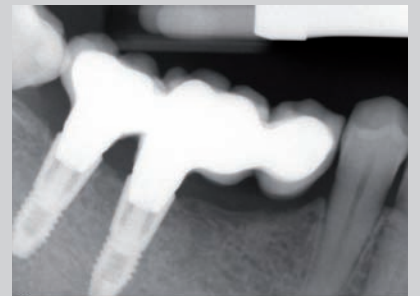
**Figure 9:** Image showing healthy keratinised mucosa around the implants after three months healing



**Figure 10:** Appearance after final fit



**Figure 11:** Occlusal view of final implant bridge



**Figure 12:** Postoperative LCPA showing baseline bone levels

area. Due to the limited height of alveolar bone, implant placement could not be carried out without some form of sinus floor manipulation. Due to this, it was decided to place implants in the lower right area, thereby restoring occlusion and masticatory function to one sides of the patient mouth at this time. A CBCT scan (Figure 6) showed adequate bone height for the placement of two Astra TechTX Osseospeed implants.

The implants were placed under local anaesthetic (Figure 7) using the Bien Air Ichiropro surgical unit. This unit has the advantage of recording the entire implant procedure, and creating a graphical representation of the insertion torques of each implant placed. The implants achieved good primary stability, and healing abutments were placed at the time

of surgery (Figure 8). Care was taken to maintain the limited keratinised mucosa around each healing abutment. The patient healed without incident, with fixture level impressions being taken three months after implant insertion (Figure 9). The implants were restored using a three unit fixed, screw-retained bridge.

The patient was delighted with the final results (Figures 10 to 12) and has been maintaining excellent oral hygiene since the work was begun.

He is due to return within three months to begin work on restoring the upper left edentulous area, as he has now consented to sinus floor manipulation. This lovely man is a very well-motivated individual, and I believe his work has an excellent long term prognosis. **IDT**